



An evidence-based algorithm for the management of common peroneal nerve injury associated with traumatic knee dislocation

Deepak Samson¹

Chye Yew Ng²

Dominic Power¹

- Traumatic knee dislocation is a complex ligamentous injury that may be associated with simultaneous vascular and neurological injury.
- Although orthopaedic surgeons may consider CPN exploration at the time of ligament reconstruction, there is no standardised approach to the management of this complex and debilitating complication.
- This review focusses on published evidence of the outcomes of common peroneal nerve (CPN) injuries associated with knee dislocation, and proposes an algorithm for the management.

Keywords: common peroneal nerve injury; complex ligamentous injury; CPN; traumatic knee dislocation; vascular injury; neurological injury; ligament reconstruction

Cite this article: *EFORT Open Rev* 2016;1:362-367. DOI: 10.1302/2058-5241.160012

Epidemiology

Knee dislocations are devastating injuries. It is estimated that this injury accounts for 0.02% of all musculoskeletal injuries.^{1,2} However this is likely to be an under-estimation as a result of spontaneous reduction and failure of recognition in some cases.^{1,3-5}

The Schenk classification⁶ and its subsequent modification is the classification currently in most common usage. The modified Schenk classification includes the presence of vascular and neurological injury.

Diagnosis

The knee dislocation may be associated with fractures, and plain radiographs should be supplemented with computed tomography (CT) where indicated. Magnetic resonance imaging (MRI) is indicated in all multi-ligament-injured

knees in order to define the injury and identify any associated osteochondral and meniscal injuries. In the setting of a peroneal nerve palsy, peripheral nerve conduction studies (NCS) and electromyography (EMG) are also useful.⁷

Ligament injuries

There is a paucity of high-level published evidence regarding the optimal management and timing for these complex injuries. However, the available evidence suggests that reconstruction is better than attempted repair⁸⁻¹¹ and should be performed early (less than three weeks), as staged surgery has a trend toward more favourable results when compared with delayed reconstruction.¹²⁻¹⁶

Vascular injury

The incidence of associated neurovascular complications has been estimated at 20% following knee dislocations.¹⁷ The popliteal artery is particularly vulnerable. All vascular injuries resulting in inadequate distal perfusion should be treated urgently with exploration and reconstruction. In such cases, a staged reconstruction of the ligamentous injury could still yield favourable results.^{1,11,16,18,19}

Common peroneal nerve injury

The Sunderland classification of peripheral nerve injury defines five grades based on the patho-anatomy and physiological changes following injury (Table 1). A sixth grade was added later to describe a mixed injury where fascicle groups have variable depths of injury, and therefore different potential for recovery.^{20,21}

In Sunderland grade 1 injuries, there is a physiological block to conduction. Function will return within 12 weeks as long as there is no residual extrinsic compression. Grade 2 injuries are favourable for recovery with rapid axonal regeneration that progresses at 2-3 mm per day, and there is no axonal misdirection. The resultant sensory and motor recovery is usually excellent. Grade 3 injuries have more potential for misdirection, and there is typically a slower rate of regeneration at around 1 mm per day. Axonal death may follow hold-up in intra-neural scar.

Table 1. The Sunderland classification of peripheral nerve injuries

Sunderland classification grade	Description
1	Conduction block +/- segmental demyelination
2	Axon discontinuity with intact endoneurium
3	Axon and endoneurium discontinuity with intact perineurium
4	Axon, endoneurium and perineurium discontinuity with intact epineurium
5	Nerve discontinuity
6	Mixed nerve injury

Recovery is typically incomplete and unpredictable. Grades 4 and 5 refer to the functional or anatomical disruption of the nerve, and there is no recovery potential without surgery. Grade 4 injuries result in neuroma-incontinuity, and grade 5 in end-neuroma formation. Grade 6 injuries refer to cases where there is good early spontaneous recovery of some motor or sensory function within the first 12 weeks, but further recovery relies on axonal re-growth which may be unpredictable.

Incidence

The reported incidence of common peroneal nerve (CPN) injury following multi-ligament knee injury varies from 4.5% to 40%.^{1,22-24} The wide range of incidence reflects the heterogeneous nature of the reported series and is likely to be related to the differing levels of energy involved in the accidents. Although the tibial nerve may also be injured, the majority of nerve injuries involve the CPN^{22,25-27} due to its course around the posterolateral knee, closely approximated to the neck of the fibula.

Traction and compression injuries involving less than 7 cm of the nerve are more likely to recover than those involving longer segments.²⁴ The deep peroneal nerve often recovers less well than the superficial nerve. This is related to the proximity of the deep nerve to the joint and the distal tether, which results in a more severe traction injury and hampers the regenerating axon progression (Fig. 1).^{28,29}

Current evidence: injury patterns and management practices

Although complete, useful functional motor recovery occurs in only about 21% of CPN injuries,²⁴ there are multiple factors affecting neurological recovery. The most consistent predictor is whether or not the injury was complete or incomplete at presentation. Krych et al²⁹ compared complete and incomplete palsies of the CPN and reported recovery rates of 38% to 83% respectively. Being younger in age is another good prognostic factor for recovery.³⁰

Defining a comprehensive management algorithm is challenging due to the heterogeneous nature of the nerve injuries. A number of strategies may be employed including observation, decompression, neurolysis, nerve grafting, nerve transfer and tendon transfer. The challenge for the treating orthopaedic surgeon lies in recognising high-grade nerve injuries such that prompt treatment may be instituted, while the selected lower-grade injuries may be released in a timely manner to prevent deterioration.

The treatment of a CPN injury depends, therefore, on whether the palsy is complete or incomplete, based on clinical examination and EMG testing. Incomplete lesions are often mixed injuries with a combination of physiological conduction block and low-grade axonal disruption. Progressive recovery is to be expected from axonal regeneration. Complete palsies at presentation without a positive Tinel sign (tingling sensation along the distribution of the nerve when the nerve is lightly tapped), or neuropathic pain with preservation of deep muscle pain represent conduction block lesions and may recover spontaneously, although some will need decompression to provide a favourable environment for recovery. Complete painful lesions with a Tinel rarely demonstrate any spontaneous recovery.³¹

Even in instances where ligament repair is deferred, early exploration of the complete nerve lesion is recommended, with intra-operative stimulation to guide subsequent management, provide an expected timeframe for recovery and ultimately an early prediction of prognosis for the patient. Extrinsic pressure from haematoma, fracture displacement or oedema may be alleviated, improving the prognosis for the continuity lesion. Neurolysis should be undertaken when there is a delay to exploration and peri-neural scar formation.³²

In the confirmed continuity lesion with distal stimulation, serial clinical examination to measure the progression of the Tinel sign is recommended one week following injury. Rapid and complete recovery is to be anticipated within three months. Neurophysiology studies with electromyography (EMG) may confirm muscle denervation with fibrillation potentials in the targeted muscle. Deep muscle tenderness on palpation is the first clinical sign of re-innervation, and is usually followed by visible contractions within a few weeks. EMG may also be used at this stage to confirm re-innervation, with polyphasic responses being typical findings. If recovery is slow, pain increases or there is deterioration of residual function then re-exploration is recommended (Table 2). If there is neuroma-incontinuity formation then this can be resected and grafted at an early stage. Typically this decision can be made with systematic repeated clinical examination by three to four months following injury.

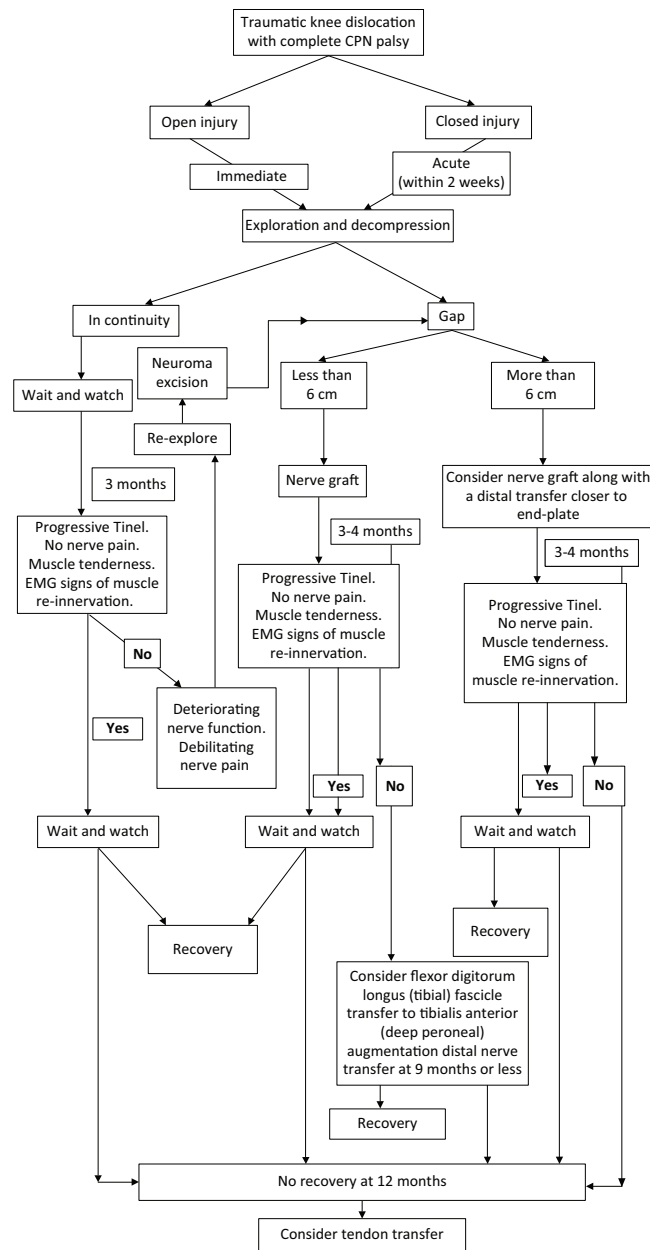


Fig. 1 Traumatic knee dislocation with complete CPN palsy.

CPN, common peroneal nerve; EMG, electromyography.

If there is a loss of continuity of the nerve at first exploration, the nerve should be debrided under the operating microscope until normal fascicular architecture is identified. Isolated nerve grafts are recommended for short nerve gaps up to 6 cm.^{32,33} Larger gaps do less well with grafting, perhaps related to the larger zone of injury. In these latter cases we recommend grafting with adjunctive distal nerve transfer from a flexor digitorum longus fascicle to the nerve to tibialis anterior.^{34,35} Early re-innervation

Table 2. Indications for nerve early exploration or re-exploration in non-healing lesions

- To provide a diagnosis
- In cases where there is doubt about the diagnosis
- Decompression
- Dislocations or displaced fracture fragments
- Deterioration in function under observation (deepening nerve lesion)
- Debilitating nerve pain
- Delay in anticipated recovery

of the tibialis anterior with the possibility of augmentation through hallux and toe extensors indicates improved chances of functional dorsiflexion in severe cases. Nerve transfer surgery can be successful up to nine months from injury before irreversible end-plate degeneration occurs at 12 months.^{34,36,37}

There have been several studies that have reported good results with nerve transfer for CPN palsy.^{38,39} However there are no large studies of early nerve transfer in the setting of complete CPN palsy associated with traumatic knee dislocation. A small series showed mixed results but surgery was typically undertaken late after failed grafting, or in isolation as a late salvage technique when recovery through an attenuated but in continuity, high-grade CPN lesion did not show any spontaneous recovery. In all cases, if there is no functional recovery then musculotendinous transfer of the tibialis posterior is a reliable salvage option.^{11,26,28,29,40,41}

Surgical options for common peroneal nerve palsy

Surgical exploration

Exploration establishes the continuity of the nerve. In the first seven days following injury the use of adjunctive intra-operative nerve stimulation must be interpreted with caution. Wallerian degeneration may not be complete and therefore it may still be possible to elicit a muscle twitch when stimulating distal to a high-grade lesion. After seven days the axonal degeneration is complete and a distal stimulation with muscle twitch confirms some axonal continuity through the zone of injury. If the stimulation is then undertaken proximal to the injured segment without a twitch, this then demonstrates a focal physiological conduction block lesion typical of segmental demyelination. Neurolysis is a useful adjunct to simple decompression in late exploration cases where established scar formation contributes to nerve ischaemia, reduced neural glide and degenerative axonopathy. Neurolysis should always be combined with intra-operative stimulation to establish nerve continuity and to demonstrate reduction in stimulation thresholds after scar release, which is a good prognostic factor.^{32,42}

Nerve repair and grafting

Nerve repair and grafting are the available techniques to deal with discontinuity of the nerve in Sunderland grade 4 or 5 lesions. Direct nerve repair is advocated with clean-cut lacerations with a healthy and vascularised nerve bed⁴³ but is not possible in ruptures associated with high-energy knee dislocations. In such cases it may be preferable to confirm the discontinuity and to tag the nerve ends with a non-absorbable monofilament suture or a radio opaque vascular clip, then refer the patient for nerve grafting if the wound precludes this at the first exploration.⁴²⁻⁴⁴

Nerve grafting typically using reversed ipsilateral sural nerve cables to bridge between fascicle groups can provide a conduit for axon re-growth across the defect.³² Kim et al have reported good results with grafts bridging distances less than 6 cm with progressively worsening outcomes as the gap increases.⁴⁵ Niall et al demonstrated that the length of the injured segment predicts recovery potential, with segments greater than 6 cm having unfavourable outcomes.²⁴ The poorer results with long grafts may represent the more severe nerve injuries, longer reinnervation times and the axonal misdirection seen when mixed motor and sensory nerves are grafted.

Nerve transfers

Nerve transfers involve the targeted transfer of expendable nerve branches or fascicles from a donor nerve with direct microscopic coaptation to the denervated muscle branch close to the motor end-plates.^{33,34,46} Nerve transfers may be used to salvage a failed recovery through a graft as a primary treatment strategy, to salvage cases with a late diagnosis or in combination with grafts as an adjunctive treatment. In recent years, nerve transfers have been gaining popularity as treatment modalities for nerve palsies in the upper and lower extremities.^{33,35,46} Keeping pace with this trend have been several studies looking into the anatomical feasibility^{37,39} as well as the outcomes of nerve transfer surgery to treat peroneal nerve palsy.^{38,39,47,48}

Early nerve transfer may prevent muscle degeneration. Appropriately-designed studies are needed in order to establish whether early nerve transfer provides more favourable results than early short segment grafting,^{34,49} although the reduced time to re-innervation provides good supportive evidence for this approach in the surgical management of nerve injuries at other sites, including the brachial plexus.³⁴

Results

Although the early results of lower limb nerve transfers show promise, longer-term studies are required to fully establish its role in the management of CPN injuries. A Medical Research Council (MRC) grade 4 power or above

is required for a lower limb muscle to be functional; studies to date report few patients achieving this level of function. However, it should be stated that the results of nerve transfers in the upper limb demonstrate improvement in function for at least three years following surgery.⁴⁷⁻⁵⁰

Giuffre et al published their results on tibial nerve fascicle transfer to the tibialis anterior, which demonstrated that four in 11 did not regain dorsiflexion of the ankle, while two in 11 were classified as MRC grade 2, one of 11 MRC grade 1, three of 11 MRC grade 3 and one of 11 regained MRC grade 4.⁵⁰ The sample size was too small and the follow-up too short to draw any meaningful conclusions, but it is the senior author's opinion that when targeted distal nerve transfer to the tibialis anterior is performed early in combination with nerve grafts, useful ankle dorsiflexion may be achieved with facilitation from weak hallux and toe extensors.

Tendon transfers

Tendon transfers have provided the most reliable outcomes in terms of regaining functional ankle dorsiflexion.^{51,52} Garozzo et al and Ferraresi et al reported outstanding results with a combined nerve repair/grafting and tibialis posterior tendon transfer. They argued that the tendon transfer enhances neural regeneration.^{27,53,54} However tendon transfers are usually performed as salvage procedures more than 12 months after injury and knee reconstruction. After 12 months the motor end-plates in denervated muscle undergo irreversible degeneration, and by two years they are mostly replaced by fat cells, rendering attempts at muscle re-innervation unsuccessful.

Conclusions

The British Orthopaedic Association Standards for Trauma (BOAST 5) guidelines on the management of peripheral nerve injury advocate early diagnosis and prompt referral to a specialist. This approach improves functional outcomes and reduces the risk of long-term debilitating neuropathic pain.^{35,38} We believe that the vascular and ligamentous priorities and the expectation of poor neurological outcome result in a failure to adequately manage the CPN injury in cases of traumatic knee dislocation. We recommend accurate and repeated examination of the nerve, early neurolysis and evaluation with the use of neurophysiological studies. Continuity lesions can then be monitored, and failure to progress can be recognised and promptly treated with re-exploration. Discontinuity lesions can be treated early with grafts and if the graft is long, or in cases where surgery is undertaken late, then the distal nerve transfer can be utilised. The suggested algorithm should be employed to guide the treating orthopaedic surgeon at the time of ligament reconstruction.

AUTHOR INFORMATION

¹The Centre for Nerve Injury and Paralysis, The Queen Elizabeth Hospital, University Hospitals Birmingham NHS Foundation Trust, UK

²The Upper Limb Unit, Wrightington Hospital, UK

Correspondence should be sent to: Mr. Deepak Samson, Queen Elizabeth Hospital, Mindlesohn Way, Edgbaston B15 2WB, UK.
Email: deepaksamson@gmail.com

CONFLICT OF INTEREST

None declared.

FUNDING

No benefits in any form have been received or will be received from a commercial party related directly or indirectly to the subject of this article.

LICENCE

©2016 The author(s)

This article is distributed under the terms of the Creative Commons Attribution-NonCommercial 4.0 International (CC BY-NC 4.0) licence (<https://creativecommons.org/licenses/by-nc/4.0/>) which permits non-commercial use, reproduction and distribution of the work without further permission provided the original work is attributed.

REFERENCES

- Lachman JR, Rehman S, Pipitone PS. Traumatic knee dislocations: evaluation, management, and surgical treatment. *Orthop Clin North Am* 2015;46:479-493.
- Wilson SM, Mehta N, Do HT, et al. Epidemiology of multiligament knee reconstruction. *Clin Orthop Relat Res* 2014;472:2603-2608.
- Cole BJ, Harner CD. The multiple ligament injured knee. *Clin Sports Med* 1999;18:241-262.
- Hegyes MS, Richardson MW, Miller MD. Knee dislocation. Complications of nonoperative and operative management. *Clin Sports Med* 2000;19:519-543.
- Peskun CJ, Levy BA, Fanelli GC, et al. Diagnosis and management of knee dislocations. *Phys Sportsmed* 2010;38:101-111.
- Schenk RC. Classification of knee dislocations. In: Gregory C. Fanelli, ed. *The multiple ligament injured knee: a practical guide to management*. New York: Springer, 2004:37-49.
- Masakado Y, Kawakami M, Suzuki K, et al. Clinical neurophysiology in the diagnosis of peroneal nerve palsy. *Keio J Med* 2008;57:84-89.
- Stannard JP, Brown SL, Farris RC, McGwin G Jr, Volgas DA. The posterolateral corner of the knee: repair versus reconstruction. *Am J Sports Med* 2005;33:881-888.
- Levy BA, Dajani KA, Morgan JA, et al. Repair versus reconstruction of the fibular collateral ligament and posterolateral corner in the multiligament-injured knee. *Am J Sports Med* 2010;38:804-809.
- Mariani PP, Santoriello P, Iannone S, Condello V, Adriani E. Comparison of surgical treatments for knee dislocation. *Am J Knee Surg* 1999;12:214-221.
- Bonnevalle P, Dubrana F, Galau B, et al; la Société Française de Chirurgie Orthopédique et Traumatologique. Common peroneal nerve palsy complicating knee dislocation and bicruciate ligaments tears. *Orthop Traumatol Surg Res* 2010;96:64-69.
- Liow RYL, McNicholas MJ, Keating JF, Nutton RW. Ligament repair and reconstruction in traumatic dislocation of the knee. *J Bone Joint Surg [Br]* 2003;85-B:845-851.
- Tzurbakis M, Diamantopoulos A, Xenakis T, Georgoulis A. Surgical treatment of multiple knee ligament injuries in 44 patients: 2-8 years follow-up results. *Knee Surg Sports Traumatol Arthrosc* 2006;14:739-749.
- Harner CD, Waltrip RL, Bennett CH, et al. Surgical management of knee dislocations. *J Bone Joint Surg [Am]* 2004;86-A:262-273.
- Levy BA, Fanelli GC, Whelan DB, et al; Knee Dislocation Study Group. Controversies in the treatment of knee dislocations and multiligament reconstruction. *J Am Acad Orthop Surg* 2009;17:197-206.
- Levy BA, Krych AJ, Shah JP, Morgan JA, Stuart MJ. Staged protocol for initial management of the dislocated knee. *Knee Surg Sports Traumatol Arthrosc* 2010;18:1630-1637.
- Keating JF. Acute knee ligament injuries and knee dislocation. In: Bentley G, ed. *European surgical orthopaedics and traumatology* New York: Springer, 2014:2949-2971.
- Gella S, Whelan DB, Stannard JP, MacDonald PB. Acute management and surgical timing of the multiligament-injured knee. *Instr Course Lect* 2015;64:521-530.
- Levy BA, Dajani KA, Whelan DB, et al. Decision making in the multiligament-injured knee: an evidence-based systematic review. *Arthroscopy* 2009;25:430-438.
- Sunderland S. A classification of peripheral nerve injuries producing loss of function. *Brain* 1951;74:491-516.
- Sunderland S. The anatomy and physiology of nerve injury. *Muscle Nerve* 1990;13:771-784.
- Twaddle BC, Bidwell TA, Chapman JR. Knee dislocations: where are the lesions? A prospective evaluation of surgical findings in 63 cases. *J Orthop Trauma* 2003;17:198-202.
- Wascher DC, Dvirnak PC, DeCoster TA. Knee dislocation: initial assessment and implications for treatment. *J Orthop Trauma* 1997;11:525-529.
- Niall DM, Nutton RW, Keating JF. Palsy of the common peroneal nerve after traumatic dislocation of the knee. *J Bone Joint Surg [Br]* 2005;87:664-667.
- Baima J, Krivickas L. Evaluation and treatment of peroneal neuropathy. *Curr Rev Musculoskelet Med* 2008;1:147-153.
- Goitz RJ, Tomaino MM. Management of peroneal nerve injuries associated with knee dislocations. *Am J Orthop (Belle Mead NJ)* 2003;32:14-16.
- Garozzo D, Ferraresi S, Buffatti P. Common peroneal nerve injuries in knee dislocations: results with one-stage nerve repair and tibialis posterior tendon transfer. *J Orthop Traumatol* 2002;2:135-137.
- Cush G, Irgit K. Drop foot after knee dislocation: evaluation and treatment. *Sports Med Arthrosc* 2011;19:139-146.
- Krych AJ, Giuseffi SA, Kuzma SA, Stuart MJ, Levy BA. Is peroneal nerve injury associated with worse function after knee dislocation? *Clin Orthop Relat Res* 2014;472:2630-2636.
- Peskun CJ, Chahal J, Steinfeld ZY, Whelan DB. Risk factors for peroneal nerve injury and recovery in knee dislocation. *Clin Orthop Relat Res* 2012;470:774-778.
- Woodmass JM, Romatowski NPJ, Esposito JG, Mohtadi NGH, Longino PD. A systematic review of peroneal nerve palsy and recovery following traumatic knee dislocation. *Knee Surg Sports Traumatol Arthrosc* 2015;23:2992-3002.
- Houdek MT, Shin AY. Management and complications of traumatic peripheral nerve injuries. *Hand Clinics* 2015;3:151-163.
- Ray WZ, Mackinnon SE. Clinical outcomes following median to radial nerve transfers. *J Hand Surg Am* 2011;36:201-208.

34. **Tung TH, Mackinnon SE.** Nerve transfers: indications, techniques, and outcomes. *J Hand Surg Am* 2010;35:332-341.
35. **Ray WZ, Mackinnon SE.** Management of nerve gaps: autografts, allografts, nerve transfers, and end-to-side neurotaphy. *Exp Neurol* 2010;223:77-85.
36. **Wood MB, Murray PM.** Heterotopic nerve transfers: recent trends with expanding indication. *J Hand Surg Am* 2007;32:397-408.
37. **White CP, Cooper MJ, Bain JR, Levis CM.** Axon counts of potential nerve transfer donors for peroneal nerve reconstruction. *Can J Plast Surg* 2012;20:24-27.
38. **Gousheh J, Babaei A.** A new surgical technique for the treatment of high common peroneal nerve palsy. *Plast Reconstr Surg* 2002;109:994-998.
39. **Nath RK, Lyons AB, Paizi M.** Successful management of foot drop by nerve transfers to the deep peroneal nerve. *J Reconstr Microsurg* 2008;24:419-427.
40. **Tomaino M, Day C, Papageorgiou C, Harner C, Fu FH.** Peroneal nerve palsy following knee dislocation: pathoanatomy and implications for treatment. *Knee Surg Sports Traumatol Arthrosc* 2000;8:163-165.
41. **Plancher KD, Siliski J.** Long-term functional results and complications in patients with knee dislocations. *J Knee Surg* 2008;21:261-268.
42. **Zachary LS, Dellon AL.** Progression of the zone of injury in experimental nerve injuries. *Microsurgery* 1987;8:182-185.
43. **Dubuisson A, Kline DG.** Indications for peripheral nerve and brachial plexus surgery. *Neurol Clin* 1992;10:935-951.
44. **Ring D, Chin K, Jupiter JB.** Radial nerve palsy associated with high-energy humeral shaft fractures. *J Hand Surg Am* 2004;29:144-147.
45. **Kim DH, Murovic JA, Tiel RL, Kline DG.** Management and outcomes in 318 operative common peroneal nerve lesions at the Louisiana State University Health Sciences Center. *Neurosurgery* 2004;54:1421-1428.
46. **Tung TH.** Nerve transfers. *Clinics in Plastic Surgery* 2014;41:551-559.
47. **Pirela-Cruz MA, Hansen U, Terreros DA, Rossum A, West P.** Interosseous nerve transfers for tibialis anterior muscle paralysis (foot drop): a human cadaver-based feasibility study. *J Reconstr Microsurg* 2009;25:203-211.
48. **Flores LP.** Proximal motor branches from the tibial nerve as direct donors to restore function of the deep fibular nerve for treatment of high sciatic nerve injuries: a cadaveric feasibility study. *Neurosurgery* 2009;65(6 Suppl):218-224.
49. **Brown JM, Tung TH, Mackinnon SE.** Median to radial nerve transfer to restore wrist and finger extension: technical nuances. *Neurosurgery* 2010;66(3 Suppl Operative):75-83.
50. **Giuffre JL, Bishop AT, Spinner RJ, Levy BA, Shin AY.** Partial tibial nerve transfer to the tibialis anterior motor branch to treat peroneal nerve injury after knee trauma. *Clin Orthop Relat Res* 2012;470:779-790.
51. **Yeap JS, Birch R, Singh D.** Long-term results of tibialis posterior tendon transfer for drop-foot. *Int Orthop* 2001;25:114-118.
52. **Molund M, Engebretsen L, Hvaal K, Hellesnes J, Husebye EE.** Posterior tibial tendon transfer improves function for foot drop after knee dislocation. *Clin Orthop Relat Res* 2014;472:2637-2643.
53. **Ferraresi S, Garozzo D, Buffatti P.** Common peroneal nerve injuries: results with one-stage nerve repair and tendon transfer. *Neurosurg Rev* 2003;26:175-179.
54. **Garozzo D, Ferraresi S, Buffatti P.** Surgical treatment of common peroneal nerve injuries: indications and results. A series of 62 cases. *J Neurosurg Sci* 2004;48:105-112.